

Research Article

Evaluation of Patient Discomfort at the Palatal Donor Site Following Free Gingival Graft Procedures: A Randomized Controlled Clinical Trial

Abubekir Eltas¹ • Şeydanur Dengizek Eltas² • Mustafa Özay Uslu^{2*} • Mustafa Ersöz³

¹Assistant Professor, Department of Periodontology, Faculty of Dentistry, Inonu University, Malatya, Turkey

²Research Assistant, Department of Periodontology, Faculty of Dentistry, Inonu University, Malatya, Turkey

³Assistant Professor, Department of Orthodontics, University of Inonu, Malatya, Turkey

*Corresponding Author; E-mail: aeltas@yahoo.com

Received: 8 April 2014; Accepted: 29 June 2014

J Periodontol Implant Dent 2014;6(2):47–53 | doi: [10.15171/jpid.2014.009](https://doi.org/10.15171/jpid.2014.009)

This article is available from: <http://dentistry.tbzmed.ac.ir/jpid>

© 2014 The Authors; Tabriz University of Medical Sciences

This is an Open Access article distributed under the terms of the Creative Commons Attribution License (<http://creativecommons.org/licenses/by/3.0>), which permits unrestricted use, distribution, and reproduction in any medium, provided the original work is properly cited.

Abstract

Background and aims. The purpose of this study was to compare the effects on patients' discomfort of four different protective methods for donor sites after free gingival graft (FGG) surgery.

Materials and methods. This study compared the effects of four different covering methods on discomfort (pain, chewing, speaking, appearance) of patients at the donor site. This study included 4 groups: Group A, periodontal dressing (PD); group B, Essix retainer, group C, modified Essix retainer and group D, modified Hawley retainer. A visual analog scale (VAS) was used to measure the experienced discomfort.

Results. The mean VAS scores for pain were higher in group A compared to those in groups with retainers for both assessments, but there was only statistical significance at T1 ($P > 0.05$). While bleeding was significantly more common in group A than in the other groups at T1 (after one week) and T2 (after two weeks) ($P < 0.05$), the differences between groups B, C, and D were not significant ($P > 0.05$). The present study showed that speaking and appearance VAS scores in the PD group were lower than those in groups with retainers ($P < 0.05$).

Conclusion. The complaints about the donor site after FGG surgery might decrease with the use of coverage techniques.

Key words: Clinical trial, free gingival graft, pain, visual analog scale.

Introduction

The free gingival graft (FGG) procedure is one of the most common approaches for gingival augmentation.¹⁻³ FGGs are used to create a widened zone of attached gingiva and reduced gingival reces-

sion.⁴

A soft tissue graft consists of retrieval of soft tissue that is completely detached from its original donor site and placed in a prepared recipient bed.⁵ The palate is the most frequent donor site for FGGs.⁶ Although it is well known that FGG is a predictable

method of root coverage, the obvious disadvantages of poor color matching and donor site morbidity render it inappropriate for use as a root coverage procedure.^{7,8} The donor site is an open wound that makes postoperative healing more painful for patients. Patient discomfort at the donor site after FGG surgery, pain and bleeding are common clinical events.⁹⁻¹²

To reduce complaints due to open wounds at the donor site, the palatal wound is generally protected with a periodontal dressing, covering the donor site with a periodontal pack for 1-2 weeks and repeating if necessary. To retain the dressing at the palatal site, a stent must usually be used.¹³ A modified Hawley retainer (MHR) is useful for covering the pack on the palate and over the edentulous ridges.¹⁴ However, the last two procedures have not been used often.

FGG is often used in periodontal plastic surgery; however, previous studies have documented the main disadvantages of FGG procedures associated with the donor site, including pain and bleeding due to open palatal wounds.^{6,15,16} Today, there is no information in the literature about the effect on patient discomfort with different coverage methods that may be useful for the donor site. Thus, the aim of this clinical study was to compare the effects on patient discomfort of four different protective methods for donor sites after FGG.

Materials and Methods

Study Population

The subjects consisted of 48 patients (24 women and 24 men) with a mean age of 30.6 years (range: 21-38 years), who were referred to the Department of Periodontology of Inonu University in Malatya, Turkey. All the patients approached agreed to participate in this study and signed an informed consent form approved by Inonu University's Local Ethics Committee.

The criteria used in selecting patients were the existence of keratinized gingiva ≤ 1 mm on the facial aspect of the mandibular anterior area generally, good periodontal health, the ability to understand verbal or written instructions, no use of systemic medications (i.e. sedatives, muscle relaxants, anti-inflammatory medications and narcotic analgesics) within the past 3 months and no record of allergies. The exclusion criteria of this study were smoking and pregnant/breast-feeding women.

Study Design and Treatment Protocols

The study design was a randomized, controlled clinical trial in one center to compare the effects of four

different covering methods on the discomfort of patients at the donor site after FGG surgery.

Each patient's age, gender and date of birth were recorded and a medical history was taken. All the patients' clinic examinations were performed four weeks before surgery, and they received periodontal therapy consisting of thorough oral hygiene instructions. The examination included assessing the plaque index (PI)¹⁷ bleeding on probing (BOP)¹⁸, probing pocket depth (PPD) and clinical attachment level (CAL). Clinical parameters were measured at six sites per tooth (mesio-buccal, buccal, disto-buccal, disto-lingual, lingual and mesio-lingual) in all the teeth, except third molars, using a Williams probe (PCP-12, Hu-Friedy, Chicago, IL, USA).

The participants in the study were selected from patients with keratinized gingiva ≤ 1 mm on the facial aspect of the mandibular anterior area, who needed to increase the width of the keratinized gingiva. Four weeks before surgery, all the patients underwent SRP and were given oral hygiene instructions. The present study was performed on 4 groups consisting of 12 patients each, selected randomly, using different coverage techniques to protect wounds in the palate: group A, periodontal dressing (PD); group B, Essix retainer (ER), group C, modified Essix retainer (MER); and group D, modified Hawley retainer (MHR). Two weeks before surgery, impressions were taken from 36 randomly selected patients. They were given ERs (n=12), MERs (n=12), and MHRs (n=12). The patients were asked to come back 1 (T1) and 2 weeks (T2) after surgery (Figure 1).

Surgical Procedure

All the patients underwent the same surgical technique; to minimize variations in the surgical technique, all the surgical procedures were carried out by one surgeon (A.E.). Briefly, the following steps were taken in the sequence described.

Recipient Site Preparation

The recipient site was prepared similar to the technique described by Langer and Langer.¹⁹ After adequate local anesthesia was obtained, a marginal, horizontal and linear incision was made in the mucogingival junction with a #15 scalpel blade. A split-thickness incision was extended distally 1 to 2 teeth farther than the planned graft area.²⁰ The raised tissue was discarded, and a periosteal bed was prepared. Gauze moistened with saline was placed over the recipient bed until graft placement.

Harvesting of the Graft

Following the establishment of anesthesia by local

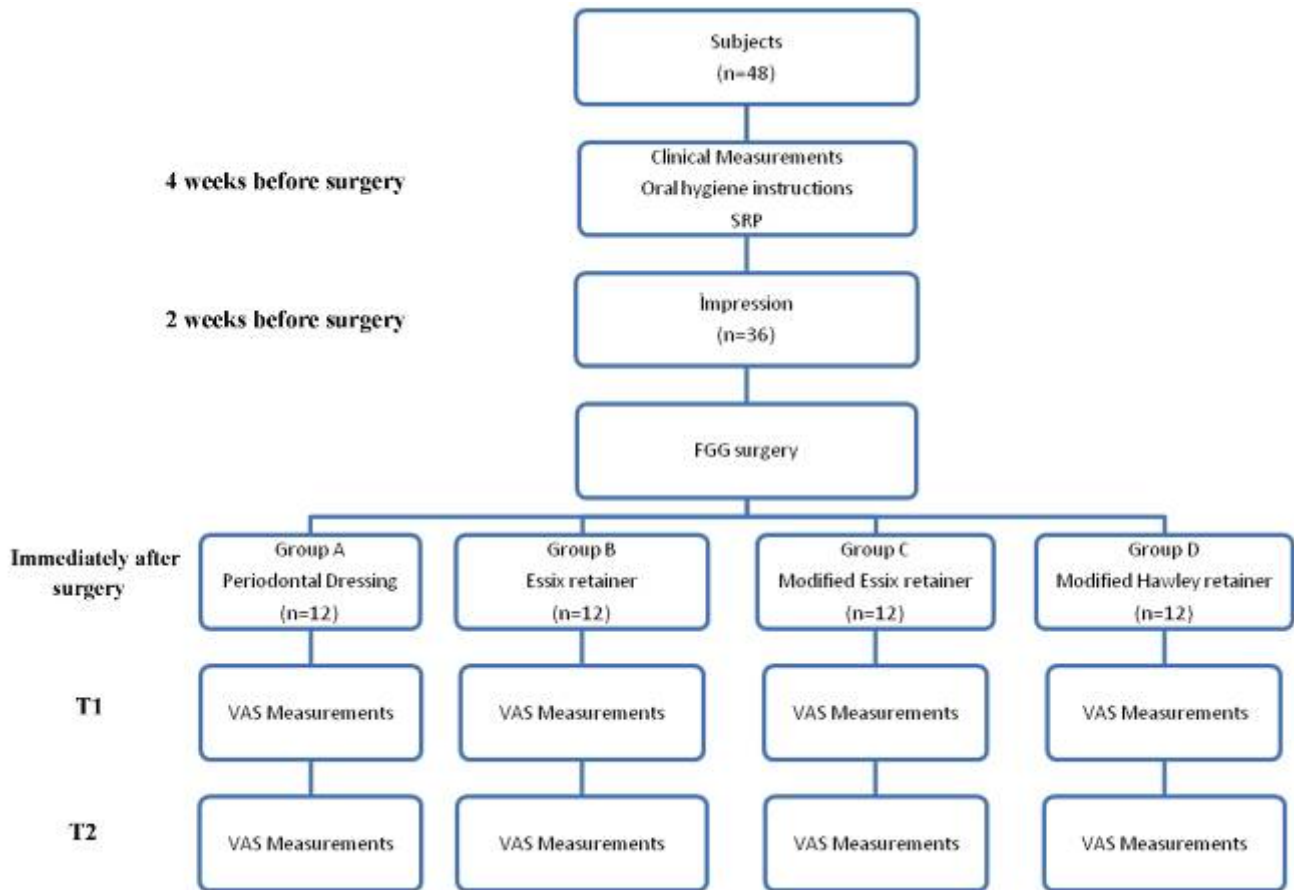


Figure 1. Study design from screening to completion of the trial. T1= 1 week after surgery; T2= 2 weeks after surgery; SRP= scaling and root planning; VAS= visual analog scale.

infiltration (2% lidocaine with 1:100,000 epinephrine), a graft was intended to be harvested from the donor region, and the area chosen to harvest the graft was between the first premolar and the first molar, located ≥ 2 mm away from the gingival margins of the corresponding teeth by a partial thickness incision (Figure 2). A #15 scalpel blade was used to harvest the tissue measuring 1-2 mm in thickness. The graft thickness was immediately confirmed with a caliper at 3 points (ends and center of the graft), and if necessary, a graft approximately 1 to 1.5 mm in thickness was obtained. The graft was then trimmed to adapt to the shape and size of the recipient site.

Graft Placement

The graft was positioned and firmly adapted to the recipient site and stabilized with knotted sutures (5-0 silk). The coronal part of the graft was positioned at the MJG level, and then the suture was tied to adapt the graft firmly in this position; no attempt was made to cover the roots. A mild compress was also applied with gauze soaked in saline for 5 minutes.

Covering the Donor Site

After a gingival graft was taken from the palate, the donor site was irrigated with sterile saline, and hemostasis was achieved with gauze moistened in saline. Later, 4 different covering techniques were applied over the donor site to protect the surgical region. In group A, the donor site was covered with periodontal dressing (Coe-Pak, GC America, Alsip, IL) (Figure 3A). An Essix retainer was adapted to

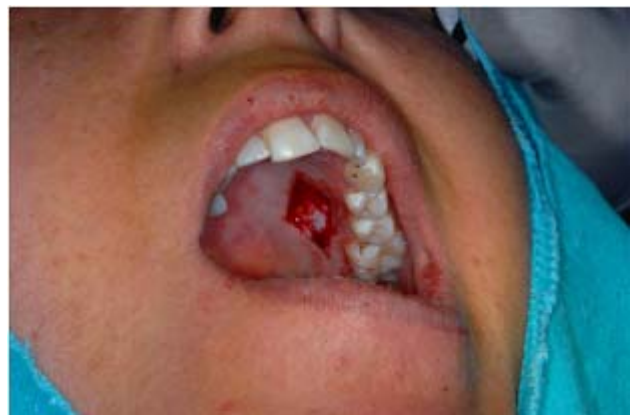

Figure 2. Image of the donor site after surgery.

the site using a regular-set periodontal dressing in group B. A modified Essix retainer was adapted to the site using a regular-set periodontal dressing in group C. A modified Hawley retainer was adapted to the site using a regular-set periodontal dressing in group D.

Postoperative Care

After surgery, routine written and oral postoperative care instructions were given to the patients. The patients were prescribed a non-steroidal anti-inflammatory analgesic for 1 week and 0.12% chlorhexidine mouthwash. The patients were instructed to rinse gently twice daily for 3 weeks. Tooth-brushing activities in the surgical sites were discontinued during this period. The sutures were removed 2 weeks after surgery. The covering methods for the donor sites were routinely used for the first 2 postoperative weeks, and the covering materials were removed 2 weeks after surgery. Patients in groups with retainers were instructed to wear their retainers full-time for 2 weeks. In group A, a new periodontal dressing was placed 1 week after surgery.

Pain and Discomfort Assessments

A VAS was used to measure postoperative pain and discomfort (chewing, speaking and appearance). The VAS was administered in a standard manner, with the initial explanation given by the same clinician to all the participants (M.O.U.). All the assessments were performed in the morning in the same clinic in a calm environment without external noise, music or conversation. All the patients were asked to define their level of discomfort on the VAS, consisting of a scale from 0 to 100 (a 10-cm line). On this scale, 0 and 100 represented “no pain or discomfort” and “the worst pain or discomfort imaginable,” respectively.

All the patients were asked to rate their bleeding experience at T1 and T2. The answers were “yes” (presence of bleeding) or “no” (absence of bleeding). Bleeding experience was calculated as a percentage as follows:

$$\text{Bleeding Score (\%)} = \frac{\text{Patients who answered "Yes" (n)}}{\text{All the patients (n = 12)}}$$

Fabrication of Essix, Modified Essix and Modified Hawley Retainers

Maxillary and mandibular alginate impressions were taken to encompass the complete dentition and one-third of the alveolus for patients in groups with retainers. A working cast was obtained. After the estimated borders of the donor site were determined on

the working cast (**Figure 2**), a metal sheet was placed, which was 1 mm wider than the borders and 2 mm thick, to create a space for periodontal dressing. This sheet was fixed on the cast with wax (**Figure 2**). In addition, an Adams hook was placed around the first molar and the hook was placed between the first and second premolars over the casts of MH retainers.

The retainers were formed by heat treatment from 1.00 mm (0.040 inches) on copolyester essix sheets (Dentsply Raintree Essix, New Orleans, Louisiana, USA), which was thermoformed to a thickness of 0.015 inches. The retainers for each group were shaped with burs and scissors. As the retainers in group B completely covered the palate, they were formed in a U shape on the palate in groups C and D. The ERs completely covered the maxillary teeth. At the same time, this retainer extended 3-4 mm onto the buccal surface of the teeth (**Figure 3B**). The MER, which was on the occlusal and buccal surfaces of the premolar and molar teeth, was similar to group B; however, it covered only the palatal surface of the incisor teeth (**Figure 3C**). The MHR covered only the palatal gingiva of all the maxillary teeth (**Figure 3D**). The retainers were adjusted for comfort. They were polished and finished.

Statistical Analysis

Data were analyzed with SPSS 16.0 (SPSS for Windows, SPSS, Chicago, IL). A descriptive analysis was conducted (mean, standard deviation, and frequency distribution) for the collected data. Friedman and Wilcoxon tests were used to evaluate the differences between T1 and T2. Differences between the groups were determined by the Kruskal–Wallis and

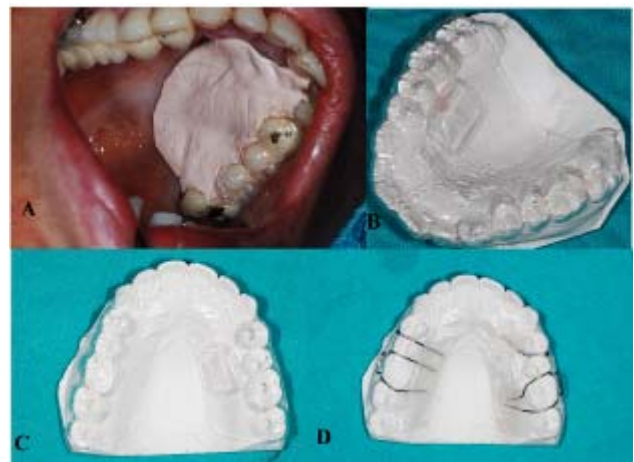


Figure 3. The application of coverage techniques . A) Periodontal dressing (Group A); B) Essix retainer (Group B); C) Modified essix retainer (Group C); D) Modified hawley retainer (Group D).

Mann-Whitney U tests. A P-value < 0.05 was considered statistically significant.

Results

The characteristics of the patient sample are presented in Table 1. The initial statistical analysis revealed no statistically significant differences in age, sex, or clinical scores (PI, BOP, PPD and CAL) between the groups at the baseline examination.

The mean changes in the VAS scores of the groups are shown in Table 2. The reduction in pain levels in all the groups between T1 and T2 was statistically significant. It was seen that the mean VAS scores for pain were higher in group A than in groups with retainers for both assessments, but there was only statistical significance at T1. There were no statistically significant differences in pain levels between groups with retainers at either T1 or T2 (Table 2).

The results demonstrated significant reductions in

chewing discomfort levels between all the groups at all the postoperative intervals (P<0.05). A statistically significant difference was not found in the patients' chewing discomfort levels between the groups at T1 (P>0.05). The mean chewing discomfort VAS scores were significantly lower in group A than in groups B, C, and D at T2 (P<0.05). There were no statistically significant pain level differences between groups B, C, and D at either T1 or T2 (Table 2).

The mean decrease in the patients' speaking discomfort from T1 was obvious at T2 in all the groups except group B (P<0.01). The VAS scores concerned with speaking discomfort were significantly lower in group A than in groups B, C, and D at both T1 and T2; in addition, scores were significantly lower in groups C and D than in group B at T1 and T2.

The present study showed that the mean change in the patients' appearance discomfort was not statisti-

Table 1. Demographic characteristics and clinical parameters of the study populations at baseline (n=48)

	Group A	Group B	Group C	Group D	p
Gender					
Male (n)	6	6	6	6	NS
Female (n)	6	6	6	6	
Age (Years; mean ±SD)	29	31	30	30	NS
Age Range (Years)	21-36	23-38	24-36	23-37	NS
PI (%; mean ± SD)	27±14	22±14	25±12	29±14	NS
BOP (%; mean ± SD)	23±12	19±10	22±10	27±13	NS
PPD (mm; mean ± SD)	3.2±0.4	3.5±0.4	3.2±0.4	3.3±0.5	NS
CAL (mm; mean ± SD)	3.2±0.4	3.3±0.5	3.1±0.5	3.2±0.4	NS

N.S. not statistically significant at P value > 0.05.

PI= Plaque index; BoP= Bleeding on probing; PPD= Probing pocket depth; CAL= clinical attachment level.

Table 2. Comparison of inter- and intra-group VAS scores (mean ± SD)

	Group A	Group B	Group C	Group D
Pain				
T1	67±19	41±13†	44±16†	45±13†
T2	30±9 c	21±9 c	23±7 c	22±6 c
Discomfort in chewing				
T1	75±23	71±23	69±19	69±22
T2	37±11 c	51±14† a	50±16† a	50±14† a
Discomfort in speaking				
T1	34±12	56±19†	45±17†‡	46±14†‡
T2	9±6 b	42±13† NS	27±12†‡ b	29±10†‡ b
Discomfort in appearance				
T1	15±11	38±19†	18±11‡	24±14‡
T2	7±5 NS	29±14† NS	10±7‡ NS	13±9‡ NS

T1 = the first week after surgery; T2 = the second week after surgery.

^a P < .05; P-values represent the difference between T1 and T2 within each treatment group.

^b P < 0.01; P-values represent the difference between T1 and T2 within each treatment group.

^c P < 0.001; P-values represent the difference between T1 and T2 within each treatment group.

† P < 0.05; P-values represent the difference from group A.

‡ P < 0.05; P-values represent the difference from group B.

cally different between T1 and T2 in all the groups. There were few complaints with regard to appearance at both assessments of patients with PD, and the scores of this group were lower than other groups. In the other groups, the appearance VAS scores were significantly higher in group B than in groups C and D at both T1 and T2.

The complaints about postoperative bleeding in all the groups are shown in Table 3. Although bleeding was significantly more common in group A than in the other groups at T1 and T2, the differences between groups B, C and D were not significant.

Discussion

This research attempted to answer questions concerning patients' discomfort with different coverage methods (PD, AS, MAS, and MH) that are used to guard the donor site after FGG surgery. The results showed significant differences between groups in postoperative patient discomfort. Pain VAS scores and postoperative bleeding in the groups with retainers were lower than those in the PD group; however, speaking and appearance VAS scores in the PD group were lower than those in the groups with retainers. This was the first study designed to compare the effects of coverage methods at the donor site for FGG on patients' discomfort.

The FGG surgical wound heals with secondary intention within 2–4 weeks, due to the removal of the epithelial layer of the palatal mucosa.²¹ Del Piezzo et al¹⁵ reported that complete epithelialization of the palatal wound occurred 4 weeks after FGG surgery. Our study was consistent with previous studies; palatal wounds healed in all the patients completely in 2–4 weeks, and no wound-healing effect was seen with any of the coverage techniques in this study.

Previously reported FGG has been associated with a high incidence of donor site pain,^{15,16,22} however, investigations on this issue have been limited. There is only one study in the literature that evaluated postoperative pain at the donor site following FGG using a VAS.¹⁶ That study showed that the mean VAS pain scores at 3 days and 3 weeks postopera-

tively were 48 and 36, respectively, for FGG subjects. In our study, the mean VAS pain scores at T1 and T2 were 41 and 21, respectively, for the AS patients (group B). The present study results were similar to those from Vessel et al's¹⁶ report for the first week; however, even the mean VAS pain score for the second week in this study was lower than Vessel et al's during the third week. In our opinion, this situation might be attributed to differences in wound healing. The present study showed that the mean pain VAS scores at T1 were higher in patients with PD than in other groups. In the present study, patients who received ER, MER and MHR experienced less pain due to a reduction in pressure over the wound at the donor site. By the second week, as epithelialization increased, pain severity decreased in all the groups. Therefore, the differences between the groups decreased during the second week, and these values were not statistically different. The results of this study concerning bleeding showed similar changes in VAS scores for pain, but bleeding scores decreased significantly from T1 to T2.

In recent years, patients' comfort has become important in healthcare.^{23,24} Thus, the aims of this study were to evaluate the effects of wound healing at the donor site after FGG surgery to determine which patients' discomfort levels were affected and to compare the effects of the different coverage techniques. According to the results of this study, important restrictions were seen in the functions related to patient comfort at the donor site. We found that these restrictions caused pain in PD users, caused by the structure of retainers. Reducing pain via increasing epithelialization in the second week might have led to an increase in patients' comfort. In groups with retainers, patients' comfort increased during the second week due to patients' increased familiarity with their retainers.

During the last decade, the most popular procedure for an edentulous mandible was to increase keratinized tissue in association with palatal mucosal grafts around the implants.^{25,26} These patients are usually older, and this process is more difficult for them to tolerate. In this respect, the importance of patients' comfort after FGG increases further. At the end of the present study, although the use of the retainers reduced pain and bleeding, ER in particular could still lead to discomfort, as evidenced by increases in the mean VAS scores concerning speaking and appearance. The reason for this situation is associated with their structures, but there are no data in the literature about the effects on daily life of retainers. In our opinion, the use of MER in patients

Table 3. Comparison of inter- and intra-group postoperative bleeding

	Postoperative bleeding			
	Group A % (n)	Group B % (n)	Group C % (n)	Group D % (n)
T1	58 (7)	17(2)†	17(2)†	17(2)†
T2	25 (3) b	8 (1)† NS	8 (1)† NS	8 (1)† NS

N.S. not statistically significant at P value > 0.05.

† P < 0.05; P-values represent the difference from group A.

b P < 0.01; P-values represent the difference between T1 and T2 within each treatment group.

with upper jaw teeth increased comfort, and the use of ER in edentulous maxilla was more useful in terms of pain.

This study showed that all the methods have some advantages and disadvantages. While MER and MHR are the most appropriate in terms of pain and bleeding, PD is most appropriate for speaking and appearance comfort. After such surgeries patients with some particular professions that necessitate comfort in speaking (for example a teacher) may not prefer a method that complicates pronunciation of words. In addition, pain and bleeding scores were higher in group A than in other groups in the first week, but scores in group A were similar to groups with retainers in the second week. Therefore, we believe there is no need for the application of retainers in the second week.

Conclusion

Complaints about the donor site after FGG surgery may be reduced with coverage techniques. In particular, MER and MHR retainers showed reductions in pain and bleeding, thus increasing patients' comfort. We believe new approaches are necessary to reduce patients' discomfort at the donor site after FGG surgery, and patients' expectations might be detrimental in selection of coverage technique after FGGs.

The authors declare that they have no financial relationship with the organization that sponsored the research.

References

1. Kissel SO, Hanratty JJ. Periodontal treatment of an amalgam tattoo. *Compend Contin Educ Dent* 2002;23:930-2.
2. Paolantonio M, Dolci M, Esposito P, D'Archivio D, Lisanti L, Di Luccio A, et al. Subpedicle acellular dermal matrix graft and autogenous connective tissue graft in the treatment of gingival recessions: A comparative 1-year clinical study. *J Periodontol* 2002;73:1299-307. doi: [10.1902/jop.2002.73.11.1299](https://doi.org/10.1902/jop.2002.73.11.1299)
3. da Silva RC, Joly JC, de Lima AF, Tatakis DN. Root coverage using the coronally positioned flap with or without a subepithelial connective tissue graft. *J Periodontol* 2004;75:413-9. doi: [10.1902/jop.2004.75.3.413](https://doi.org/10.1902/jop.2004.75.3.413)
4. Harris RJ. Gingival augmentation with an acellular dermal matrix: Human histologic evaluation of a case placement of the graft on periosteum. *Int J Periodontics Restorative Dent* 2004;24:378-85.
5. Lorenzana ER, Allen EP. The single-incision palatal harvest technique: A strategy for esthetics and patient comfort. *Int J Periodontics Restorative Dent* 2000;20:297-305.
6. Zucchelli G, Mele M, Stefanini M, Mazzotti C, Marzadori M, Montebugnoli L, et al. Patient morbidity and root coverage outcome after subepithelial connective tissue and de-epithelialized grafts: a comparative randomized-controlled clinical trial. *J Clin Periodontol* 2010;37:728-38. doi: [10.1111/j.1600-051x.2010.01550.x](https://doi.org/10.1111/j.1600-051x.2010.01550.x)
7. Miller PD Jr. Root coverage using free soft tissue autograft following citric acid application, III: A successful and predictable procedure in areas of deep-wide recession. *Int J Periodontics Restorative Dent* 1985;5:14-37.
8. Remya V, Kishore Kumar K, Sudharsan S, Arun KV. Free gingival graft in the treatment of class III gingival recession. *Indian J Dent Res* 2008;19:247-52. doi: [10.4103/0970-9290.42959](https://doi.org/10.4103/0970-9290.42959)
9. Curtis JW Jr, McLain JB, Hutchinson RA. The incidence and severity of complications and pain following periodontal surgery. *J Periodontol* 1985;56:597-601.
10. Miller PD. Root coverage with the free gingival graft: Factors associated with incomplete coverage. *J Periodontol* 1987;58:674-81. doi: [10.1902/jop.1987.58.10.674](https://doi.org/10.1902/jop.1987.58.10.674)
11. Wang HL, Bunyaratavej P, Labadie M, Shyr Y, MacNeil RL. Comparison of 2 clinical techniques for treatment of gingival recession. *J Periodontol* 2001;72:1301-11. doi: [10.1902/jop.2001.72.10.1301](https://doi.org/10.1902/jop.2001.72.10.1301)
12. Silva CO, Ribeiro PE, Sallum AW, Tatakis DN. Free gingival grafts: graft shrinkage and donor-site healing in smokers and non-smokers. *J Periodontol* 2010;81:692-701. doi: [10.1902/jop.2010.090381](https://doi.org/10.1902/jop.2010.090381)
13. Wennstrom JL, Zucchelli G, Prato GPP. Mucogingival therapy - periodontal plastic surgery. In: Lindhe J, Lang NP, Karring T, eds. *Clinical Periodontology and Implant Dentistry*, 5th ed. Iowa; Blackwell Publishing Ltd; 2008. p. 955-1011.
14. Carranza FA. Clinical diagnosis. In: Newman MG, Takei HH, Carranza FA, eds. *Clinical Periodontology*, 9th ed. Philadelphia: WB Saunders; 2002. p. 432-53.
15. Del Pizzo M, Modica F, Bethaz N, Priotto P, Romagnoli R. The connective tissue graft: a comparative clinical evaluation of wound healing at the palatal donor site. A preliminary study. *J Clin Periodontol* 2002;29:848-54. doi: [10.1034/j.1600-051x.2002.290910.x](https://doi.org/10.1034/j.1600-051x.2002.290910.x)
16. Wessel JR, Tatakis DN. Patient outcomes following subepithelial connective tissue graft and free gingival graft procedures. *J Periodontol* 2008;79:425-30. doi: [10.1902/jop.2008.070325](https://doi.org/10.1902/jop.2008.070325)
17. O'Leary TJ, Drake RB, Naylor JE. The plaque control record. *J Periodontol* 1972;43:38. doi: [10.1902/jop.1972.43.1.38](https://doi.org/10.1902/jop.1972.43.1.38)
18. Lang NP, Nyman S, Senn C, Joss A. Bleeding on probing as it relates to probing pressure and gingival health. *J Clin Periodontol* 1991;18:257-61. doi: [10.1111/j.1600-051x.1991.tb00424.x](https://doi.org/10.1111/j.1600-051x.1991.tb00424.x)
19. Langer B, Langer L. Subepithelial connective tissue graft technique for root coverage. *J Periodontol* 1985;56:715-20. doi: [10.1902/jop.1985.56.12.715](https://doi.org/10.1902/jop.1985.56.12.715)
20. Mörmann W, Schaer F, Firestone AR. The relationship between success of free gingival grafts and transplant thickness. Revascularization and shrinkage-a one year clinical study. *J Periodontol* 1981;52:74-80. doi: [10.1902/jop.1981.52.2.74](https://doi.org/10.1902/jop.1981.52.2.74)
21. Farnoush A. Techniques of protection and coverage of the donor sites in free soft tissue graft. *J Periodontol* 1978;49:403-5. doi: [10.1902/jop.1978.49.8.403](https://doi.org/10.1902/jop.1978.49.8.403)
22. Griffin TJ, Cheung WS, Zavras AI, Damoulis PD. Postoperative complications following gingival augmentation procedures. *J Periodontol* 2006;77:2070-9. doi: [10.1902/jop.2006.050296](https://doi.org/10.1902/jop.2006.050296)
23. D'Avila GB, Carvalho LH, Feres-Filho EJ, Feres M, Leao A. Oral health impacts on daily living related to four different treatment protocols for chronic periodontitis. *J Periodon-*

- tol 2005;76:1751-7. doi: [10.1902/jop.2005.76.10.1751](https://doi.org/10.1902/jop.2005.76.10.1751)
24. O'Dowd LK, Durham J, McCracken GI, Preshaw PM. Patients' experiences of the impact of periodontal disease. *J Clin Periodontol* 2010;37:334-9. doi: [10.1111/j.1600-051x.2010.01545.x](https://doi.org/10.1111/j.1600-051x.2010.01545.x)
25. Sclar AG. Beyond osseointegration. In: Sclar AG, ed. *Soft Tissue and Esthetic Considerations in Implant Dentistry*. Chicago: Quintessence; 2003. p. 1-12.
26. Ono Y, Nevins M, Cappetta EG. The importance of keratinized tissue for implants. In: Nevins M, Mellonig JT, eds. *Implant Therapy—Clinical Approaches and Evidence of Success*. Chicago: Quintessence; 2003. p. 227-37.