

# Implant-supported Overdenture with Slight Lingual Perforation in the Mandible: A Case Report

**Farhan Durrani<sup>1</sup>\*•Royana Singh<sup>2</sup>**

<sup>1</sup> Associate Professor, Department of Periodontics and Oral Surgery, Faculty of Dental Sciences, Institute of Medical Sciences

<sup>2</sup> Associate Professor, Department of Anatomy, Institute of Medical Sciences, Banaras Hindu University, Varanasi -221005, India

\*Corresponding Author; Email-docfarhan@rediffmail.com

Received: 18 August 2012; Accepted: 23 October 2012

J Periodontol Implant Dent 2012; 4(2):77-80

This article is available from: <http://dentistry.tbzmed.ac.ir/jpid>

© 2012 The Authors; Tabriz University of Medical Sciences

This is an Open Access article distributed under the terms of the Creative Commons Attribution License (<http://creativecommons.org/licenses/by/3.0>), which permits unrestricted use, distribution, and reproduction in any medium, provided the original work is properly cited.

---

## Abstract

Placement of the dental implant has become a popular option for oral rehabilitation in edentulous patients. The inter-foraminal area of the anterior mandible has become the elective area for the placement of implants. This area is also prone to vascular accidents because of the rich vascular anastomoses that supply this area. We present a case of slight perforation of one of the implants during surgery which just missed the sublingual branch. It was followed for a period of one year and no relevant complications were seen.

**Key words:** Implants, lingual perforation, mandible, sublingual artery.

---

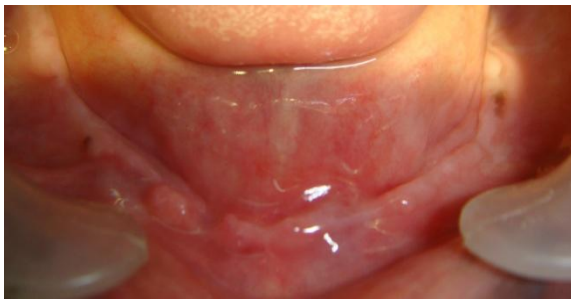## Introduction

**P**lacement of endosseous dental implants has become a very popular option for comprehensive oral rehabilitation in both partially and completely edentulous patients.<sup>1</sup> In edentulous patients, implant placement in the anterior mandible has become common for stability and maintenance of complete dentures in the inter-foraminal area.<sup>2</sup> Implant-supported overdentures in the mandible provide predictable results with improved stability, retention, function and patient satisfaction compared to conventional dentures. Implants placed in anterior mandible have a success rate up to or greater than 95%.<sup>3</sup> The inter-foraminal region is the elective area in the mandible for implant placement in edentulous and

atrophic cases and has been recognized as a safe area without serious complications.<sup>4</sup>

However, among the intraoperative complications related with surgery, hemorrhagic accidents occur most frequently in the inter-foraminal region since the majority of vascular branches from the sublingual as well as the mental artery located towards the lingual side of anterior mandible parallel to genioglossus muscle anastomose during their course and enter the mandibular bone in this region. Mandibular fractures, secondary to implant placement, occur more easily when placing implants in the atrophic mandible. Occasionally, incorrect positioning or lack of relative parallelism in placing implants result in lingual plate perforation or damage to adjacent teeth.<sup>5</sup> Surgical accidents and complications do occur during surgery, healing or even after function.<sup>6</sup>

In the anterior mandibular region it is rare to find a lingual undercut but it might be a finding which can be a problem during implant placement. The use of conventional or computed tomography (CT) is usually advocated for pre-operative implant planning because a cross-sectional view provides a proper visualization of the anatomy of the surgical site.<sup>7</sup> American Academy of Oral and Maxillofacial Radiology (AAOMR) has recommended the inclusion of cross-sectional imaging to evaluate any potential implant site prior to its placement. In fact, the paper also admits that there is no evidence to support this statement because the indiscriminate use of dental imaging, especially conventional and CT, can be potentially harmful to the patient when the cost and radiation doses are considered.<sup>8</sup>



**Figure 1. Initial atrophic jaw.**

Knowledge of anatomical structures and their relation to the site of interest, together with accurate planning of the case, are probably the best way to avoid surgical complications.

The aim of this article is to present a case of lingual perforation of the mandible by implant in an atrophic edentulous jaw.

### Case Report

The patient, a 67-year-old man with atrophic mandible and resorbed alveolar ridge (Figure 1), presented to the Faculty of Dental Sciences, Banaras Hindu University Varanasi, with dissatisfaction with the existing lower denture. The ridge was classified as Type 2 Division according to Misch Classification of edentulous arches. The biomechanics of this arch might have indicated a removable restoration to improve long-term success. Root-form implants may be used in the anterior region by doing some osteoplasty. The patient was asymptomatic and had an unremarkable medical history. He was referred to his physician for a complete physical examination, which ruled out any undiagnosed medical condition. Under local anesthesia (articaine HCl 40 mg/mL with epinephrine 1:100 000) (Alfacaina, Weimer Pharma,

Rastatt, Germany), a full-thickness mucoperiosteal flap was elevated only on the buccal side, leaving the palatal aspect undisturbed. During the surgery all modalities of proper placement of implants were tried to get equal distance of each implant from each other as well as without any angulations. The patient received four submerged screw-type implants (13 mm long and 4.3 mm wide). At the time of placement, one implant perforated the lingual plate of mandible (Figure 2), which was tightened with cover screw as primary stability was achieved. After one month one of the three implants other than the problematic perforated implant failed, which was replaced by a 10-mm-long and 5.3-mm-wide implant with a little wider diameter (Figure A). The other three implants were stable and were without any complications, which included the perforated implant.

After the surgery, antibiotics were given (amoxicillin 500 mg) four times daily along with analgesics for seven days. The patient was thoroughly instructed in home care and closely followed throughout the course of healing.

After a period of one year prosthesis fabrication was started; during this one-year period the patient continued with the existing denture. Retentive system chosen for the overdenture was bar attachment with clips: a titanium alloy bar without cantilevers on either side, rigidly connected to all four implants, which had abutments of 2 mm in size for three normal implants, and the perforated implant was 4 mm. The clips were cured into the denture and a well-balanced occlusion was achieved keeping in mind the anterior posterior distance from the last and first implant; then the prosthesis was delivered to the patient (Figure 3). Hader bar and clip system was ideal for decreased prosthesis movement in the above-mentioned situation.

### Discussion

In edentulous patients, in particular in those with severe resorption of the alveolar bone of the mandible, the possibility of injury due to lingual perforation of blood vessels is high. Several authors have reported that severe hemorrhage of the floor of the mouth, which could result in life-threatening obstruction of upper respiratory tract due to edema and elevation of tongue after perforation of the lingual cortex. This can be fatal and requires immediate intervention.

Quirynen et al<sup>10</sup> and Tepper et al<sup>11</sup> have reported the size of the mandible using CT with the main focus on interforaminal region. They described three different

jaw bone morphologies: type-I with clear lingual concavity, type-II with a slope of the lingual cortex and type-III with bone widening in caudal direction. However, the caudal part of the jaw remains unchanged after tooth extraction until the later stages of resorption (Leckhom and Zarb 1985).

In types I and II there is an increase in the chance of perforation if wider implants are used. The risk of perforation in the buccal and lingual plate increases in type I. Type II bone is more closely related to degree of tilting and inclination of the bone (linguoversion); the lower the slope, the higher is the risk of perforation.

In our case it was type II morphology with the ridge more in linguoversion, which could have led to the perforation with one of the implants near the mental foramen on the left side. Salvatorc Longoni et al<sup>4</sup> conducted a study on mandibles to define the positions and dimensions of lingual vascular canals, concluding that lingual canal was on the midline and other typical localizations were the second incisor and the first premolar regions.

Kalpidis and Setayesh<sup>12</sup> and Chan et al<sup>13</sup> have reported that the branches of sublingual and submental arteries might be in close proximity to the mandible region.

Since four implants were used in the anterior mandible and in order to get absolute parallelism, they were placed equidistant from each other. This could have led to the perforation of the lingual cortex. The blood supply to the floor of the mouth and paralingual tissue of the anterior mandibular region has been derived from submental artery, a branch of facial artery. While sublingual artery is one of the terminal branches of lingual artery, the sublingual as well as the submental artery anastomose to form extensive network at the floor of the mouth. However, our implant just missed the sublingual artery. It courses between the genioglossus muscle and sublingual salivary gland to anastomose with a similar artery from the other side, which was barely 0.5 mm away from the tip of the implant (Figure 4). Therefore, bleeding complication was just missed.

A misdirected osteotomy that penetrates the lingual cortex can sever the branch of an artery, causing a life-threatening situation. Atrophic ridges do have arteries lying against the mandible; therefore, an implant surgeon should be well versed in arterial supply of the mandible and techniques to arrest bleeding and maintain the airway if such an artery gets perforated.

In our case we waited one year for any obvious mishaps or failures, but as implants were integrated, the load was distributed through the bar-retained attachment. The implants have been in function for last four years without any swelling, mobility or friction and any elevation in the floor of the mouth.

In the authors' opinion, proper planning and careful surgery is a must for any implant drilling procedure. However, if there is a slight perforation with no obvious complications and there are other implants next to it, splinting of all the implants and bar fabrication with hybrid prosthesis can be a choice. The overdenture should be retained by at least four implants for better distribution of forces. This opinion is just the authors' viewpoint, which needs further investigation.

## References

1. Leong DJM, Chan HL, Yeh CY, Takarakis N, FU JH, Wang HL. Risk of lingual plate perforation during implant placement in the posterior mandible: A human cadaver study. *Implant Dentistry* 2011; 20(5):360-363.
2. Jo J, Kim S, and Oh J. Hemorrhage related to implant placement in the anterior mandible. *Implant Dentistry* 2011; 20(3):e33-36.
3. Doundoulakis JH, Eckert SE, Lindquist CC, Jeffcoat MK. The implant-supported overdenture as an alternative to the complete mandibular denture. *J Am Dent Assoc* 2003; 134(11):1455-1458.
4. Longoni S, Sartori M, Braun M, Bravetti P, Lapi A, Baldoni M, Tredici G. Lingual vascular canals of the mandible: Risk of bleeding complications during implant procedures. *Implant Dentistry* 2007; 16 (2):131-133.
5. Pelayo JL, Diago MP, Bowen EM, Diago MP. Intraoperative complications during oral Implantology. *Med Oral Patol Oral Cir Buccal* 2008; 13(4)E: 239-43.
6. Greenstein G, Cavollaro J, Romanos G, Tarnow D. Clinical recommendations for avoiding and managing surgical complications associated with implant dentistry: a review. *Journal of Periodontology*. 2008; 79(8):1317-29.
7. Chen LC, Lundgren T, Hallstrom H, Cherel F. Comparison of different methods of assessing alveolar ridge dimensions prior to dental implant placement. *Journal of Periodontology* 2008; 79(3): 401-5.
8. Chan HL, Brooks SL, Fu JH, Yeh CY, Rudek I, Wang HL. Cross-sectional analysis of the mandibular lingual concavity using cone beam computed tomography. *Clin Oral Impl Res* 2011; 22: 201-206.
9. Tepper G, Hofschneider UB, Ganleitner A, Ulm C. Computed tomographic diagnosis and localization of bone canals in mandibular interforaminal region for prevention of bleeding complications during implant surgery. *The International Journal of Oral Maxillofacial Implants* 2001; 16: 68-72.
10. Kalpidis CD, Stayesh RM. Haemorrhaging associated with endosseous implant placement in the anterior mandible: a review of the literature. *Journal of Biotechnology* 2004; 75: 631-645.

11. Kalpidis CD, Konstantinidis AB. Critical hemorrhage in the floor of the mouth during implant placement in the first

Mandibular Premolar position: a case report. *Implant Dentistry* 2005;14:117-124.

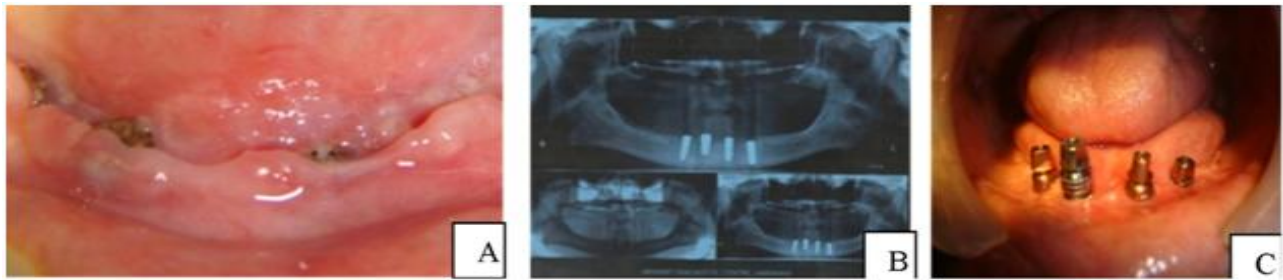


Figure 2. A: Three weeks after healing, one implant cannot be seen as it is below the soft tissue. B: Orthopantomogram showing the four implants. C: Impression transfers on four implants after six months of healing.

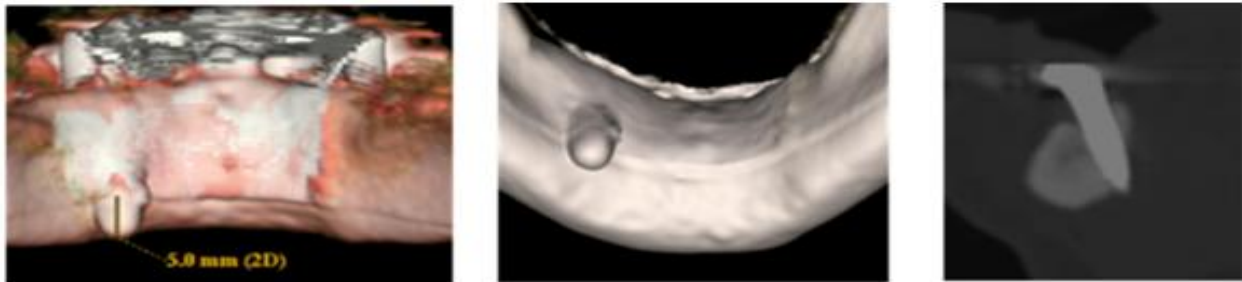


Figure 3. Lingual plate perforation by the implant.