

## Case Report

# Guided Bone Regeneration with Bone Expansion for Implant Placement in Atrophic Maxilla: A Case Report

Krishna Kumar Gupta<sup>1\*</sup> • Chetan Chandra<sup>2</sup> • Jagriti Gupta<sup>3</sup> • Gurpreet Dhinsa<sup>4</sup>

<sup>1</sup> Professor, Department of Periodontology and Implantology, Sardar Patel Post Graduate Institute of Dental & Medical Sciences, Lucknow, India

<sup>2</sup> Senior lecturer, Sardar Patel Post Graduate Institute of Dental & Medical Sciences, Lucknow, India

<sup>3</sup> Post graduate student (IIIYr), Sardar Patel Post Graduate Institute of Dental & Medical Sciences, Lucknow, India

<sup>4</sup> Post graduate student (IIYr), Sardar Patel Post Graduate Institute of Dental & Medical Sciences, Lucknow, India

\*Corresponding Author; E-mail: drkkgupta26@rediffmail.com

Received: 2 December 2010; Accepted: 8 April 2011

J Periodontol Implant Dent 2011; 3(1): 43-46

This article is available from: <http://dentistry.tbzmed.ac.ir/jpid>

© 2011 The Authors; Tabriz University of Medical Sciences

This is an Open Access article distributed under the terms of the Creative Commons Attribution License (<http://creativecommons.org/licenses/by/3.0>), which permits unrestricted use, distribution, and reproduction in any medium, provided the original work is properly cited.

---

## Abstract

Lack of sufficient bone to place an implant at the most functionally and esthetically appropriate position is a common problem, especially in the maxillary anterior esthetic zone region. A surgical bone spreading technique is proposed to augment the alveolar ridge for horizontal defects through a localized alveolar osteotomy and interpositional bone graft. Bone spreading technique (BST) is horizontal augmentation with minimal trauma for simultaneous implant placement. The foremost advantage of this method is that the buccal wall expands after the medullar bone is compressed against the cortical bone. The lateral dilation and compaction of the medullar bone enhances primary stability.

**Key words:** Deficient alveolar bone width, ridge expansion, bone spreading technique, dental implant, guided bone regeneration.

---

## Introduction

One of the major problems encountered after tooth extraction is the hard and soft tissue loss around the socket. Reduction of the buccal alveolar bone caused by bone resorption in partially edentulous maxilla is a frequent problem.<sup>1,2</sup> Implants need an adequate volume of bone to stabilize the fixture; thus partially edentulous patients with maxillary atrophy require to be augmented. Numerous augmentation techniques have been reported in dental literature to facilitate implant placement in atrophic ridges

using block grafts, which require several steps before prosthetic restoration.<sup>3,4</sup>

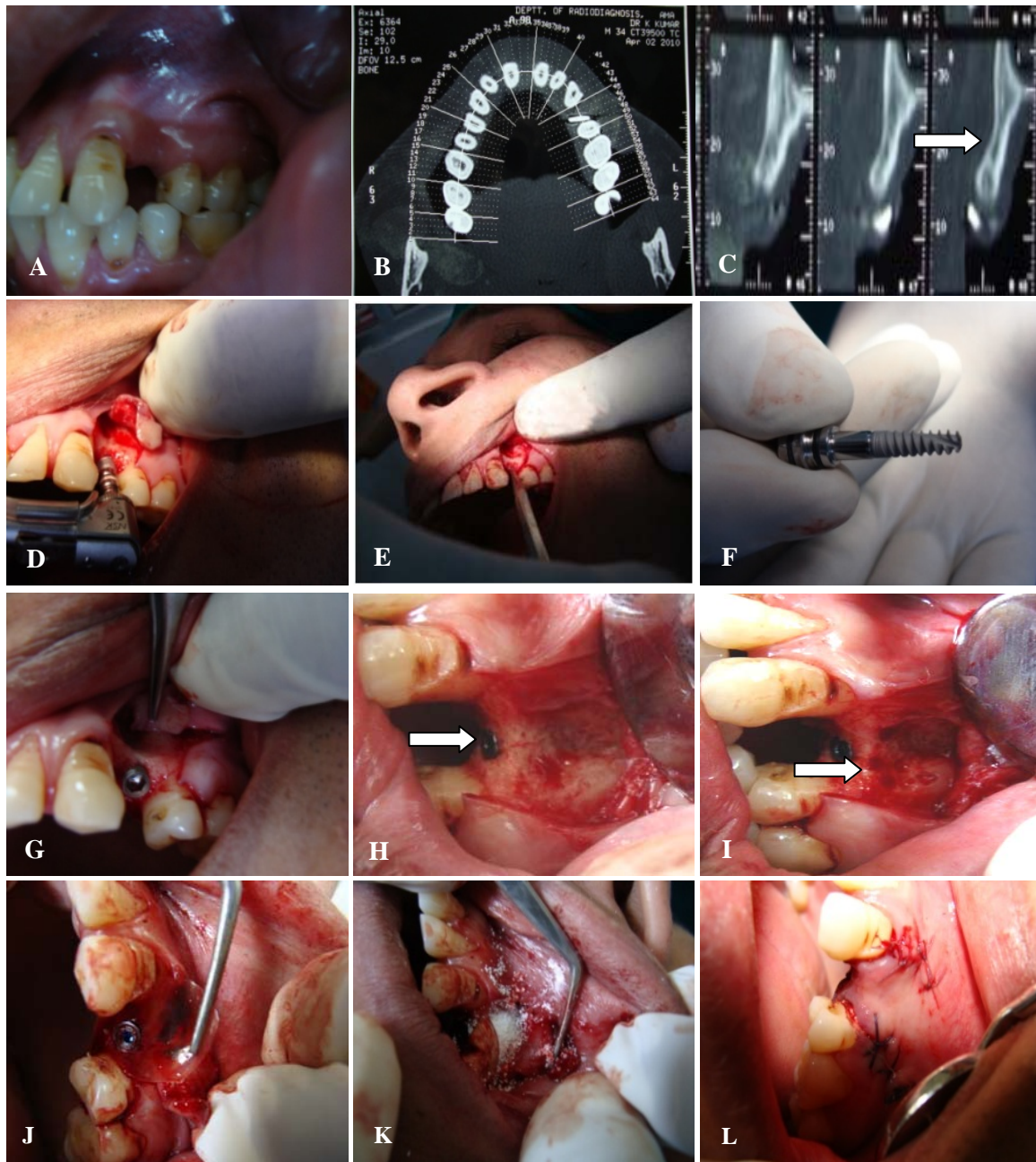
This is a technique which would both lessen the trauma to patient and preserve maximum amount of alveolar bone at the precise site anticipated. Spreaders of increasing diameters are gently introduced sequentially to expand the implant site.<sup>5,6</sup> With each insertion of a larger diameter spreader the bone is pushed laterally. The implant should be larger in diameter than the site created by the largest diameter spreader. This paper presents a case wherein a technique for widening the maxillary cortical bone was

carried out to improve the placement of an implant.<sup>7,8</sup>

### Case report

A 38-year-old male patient reported to the Department of Periodontology and Implantology with a chief complaint of missing tooth and asked for treatment. Oral examination revealed missing left maxillary first premolar (#24) with significant buccal

bone loss but adequate ridge height which favored implant placement (Figure 1A). Dental investigation was carried out, including intraoral periapical radiograph, orthopantomograph (OPG) and Dentascan along with routine blood investigations. The treatment plan was placement of an SPI (Spiral Implant) root form implant along with a regenerative technique which included bone graft (Ostoform<sup>TM</sup>) and



**Figure 1.** (A) Preoperative view of the patient. (B) Preoperative CT. (C) CT showing horizontal defect. (D) Pilot drilling. (E) Increasing diameter with spreaders. (F) 3.3-mm diameter SPI root form implant. (G) Implant placement. (H) Implant threads are visible due to very small amount of bone buccally. (I) Before placement of graft, bleeding bed was prepared by a round bur. (J,K) GTR membrane was cut to match the size of the defect and placed over the area along with placement of bone graft. (L) Flap repositioning and suturing.

GTR (Guided Tissue Regeneration) membrane (Periocol™) to enhance bone formation in that region.

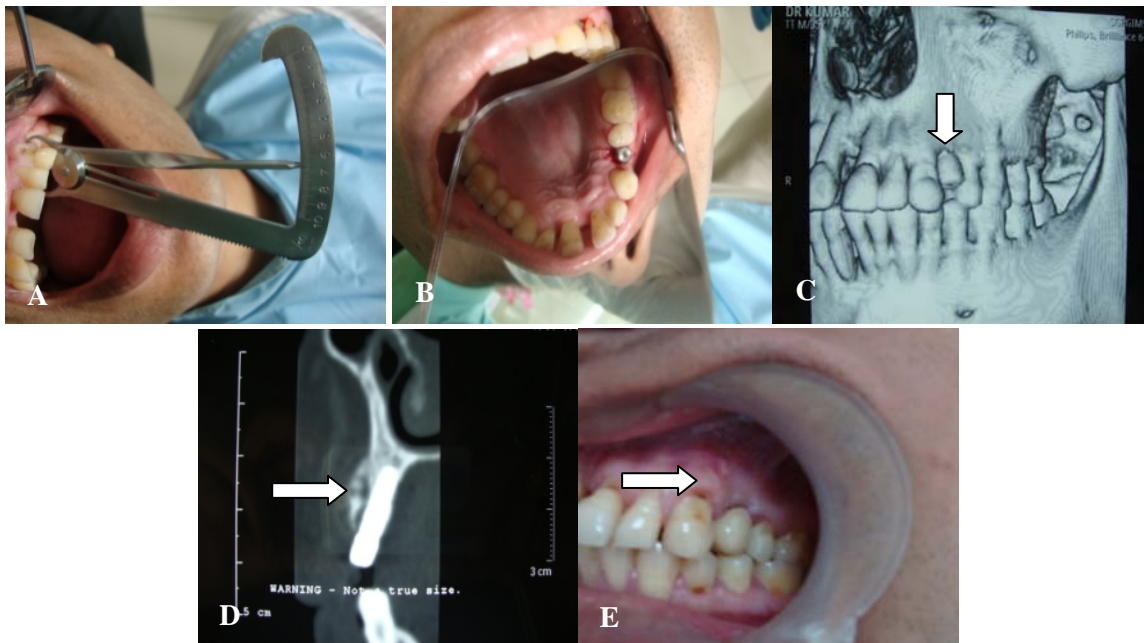
The Dentascan measurements of the partial edentulous maxilla showed 4 mm of buccolingual bone and 15 mm of bone height. Therefore, it was decided to place an implant with a length of 11.5 mm and a diameter of 3.3 mm (Figures 1B,C).

#### *Surgical technique*

A crestal incision was made over the defect and was continued in the gingival sulcus of the teeth adjacent to the edentulous space. Mesial and distal releasing incisions were given to achieve easy movement of the buccal flap. Subperiosteal exposure on the buccal side was initiated and showed further bone concavity on buccal aspect. To secure a proper alignment of the implants, a surgical template was used. The proposed implant site was clearly marked with the help of a pilot drill under copious irrigation with chilled normal saline (Figure 1D). The osteotomy prepared with the help of pilot drill was further expanded with the help of a series of spreaders in a progressive manner. Spreaders of increasing diameter (first 2.15 mm and then 2.5 mm) were gently introduced sequentially to expand the implant site (Figure 1E). With each insertion of a larger diameter spreader the bone was pushed laterally. Care was taken to pro-

ceed as slowly as possible to avoid any fracture of bone.

Finally the osteotomy site was laterally expanded to receive 3.3-mm diameter SPI root form implant (Figures 1F,G). The implant achieved primary stability and was checked with the help of torque ratchet set at a maximum of 40 N/cm<sup>2</sup>. After placement of the implant, implant threads were visible as there was a very small amount of bone buccally. The Periocol™ GTR membrane was cut to match the size of the defect and placed over the area along with placement of bone graft. Before placement of graft, bleeding bed was prepared by a round bur (Figures 1H-K). The flap was repositioned and sutured using 3.0 Mersilk sutures (Figure 1L). The patient was provided with home care instructions, i.e. not to rinse the mouth vigorously and use ice packs over the surgical area during the first 24 hours after the operation. The patient was kept on antibiotics and analgesics along with 0.02% chlorhexidine gluconate mouthwash for 5 days. The sutures were removed on the seventh postoperative day. The patient was recalled for a follow-up after 3 months to evaluate the formation of bone in the defect region with the help of CT scan (Dentascan). Bone formation was measured and gingival former was placed (Figure 2).



**Figure 2.** (A) Measurement of bone formation. (B) Placement of gingival former. (C,D) Evaluation of bone formation in the defect region with CT scan image (Dentascan). (E) Clinical view of enhanced bone with implant abutment in place.

### Discussion

The ultimate objective of implant treatment is to provide replacement of missing teeth. As with any treatment, pre-surgical planning is crucial for success. In response to changing treatment concepts, different surgical approaches in implant placement have been developed, including implant placement following cortical plate expansion in maxilla. The correction of horizontal alveolar ridge defects to place dental implants can be achieved through several techniques such as autogenous grafting, horizontal guided bone regeneration and bone spreading technique.<sup>9</sup> Bone spreading technique (BST) is horizontal augmentation with minimal trauma for simultaneous implant placement and is a better and economical alternative of conventional method of bone tapping with Summer's osteotome. At diagnosis and treatment plan the available bone was 15 mm in length and 4 mm in width. The preoperative Dentascan revealed that there was a horizontal bone defect on the buccal side leaving inadequate bone volume buccolingually for placement of desired implant.

Therefore, an implant with a length of 11.5 mm and a diameter of 3.3 mm was selected along with placement of bone graft and Periocol™ GTR membrane in order to resolve the horizontal bone defect and achieve implant stability.<sup>10</sup> The patient was recalled after three months for the placement of gingival former. The patient was sent for the post-operative Dentascan which revealed bone formation. At the beginning of the study bone measured 4 mm buccolingually, which housed an implant with a diameter of 3.3 mm so the bone was  $4 - 3.3 = 0.7$  mm. After the placement of implant by regenerative technique the actual bone measured 9 mm buccolingually. The initial bone amount was 4 mm. After 3 months it was 9 mm so the gain showed  $9 - 4 = 5$  mm but 0.7 mm of bone was already present as bone housing implant; therefore, the overall gain in bone was  $5.0 - 0.7 = 4.3$  mm.

### Conclusion

BST for horizontal ridge augmentation with implant placement has been shown to be predictable and successful in treating the maxilla with deficient alveolar bone width. BST is superior to drilling technique for application in soft maxillary bone. Implant placement was carried out along with bone graft and Periocol™ GTR membrane which helped resolve the defect by formation of bone. This had a great advantage of overcoming the problem of the defect, hence maintaining the stability of the implant.

### References

1. Bernhart T, Weber R, Mailath G et al. Use of crestal bone for augmentation of ridges prior to of extremely knife-edge alveolar ridges prior to implant placement: report of 3 cases. *Int J Oral Maxillofac Implants* 1999; 14:424-7.
2. Tinti C, Parma-Benfenati S. Clinical classification of bone defects concerning the placement of dental implants. *Int J Periodont Restorat Dent* 2003;23:147-55.
3. Jensen J, Sindet- Pedersen S. Autogeneous mandibular bone grafts and osseointegrated implants for reconstruction of the severely atrophied maxilla: a preliminary report. *J Oral Maxillofac Surg* 1991;49:1277-87.
4. Misch CM, Misch CE. The repair of localized severe ridge defects for implant placement using mandibular bone grafts. *Implant Dent* 1995;4:261-7.
5. Shulman LB. Surgical considerations in implant dentistry. *J Dent Edu* 1988; 52:712-20.
6. Summers RB. Maxillary implant surgery. The osteotome technique. Part-I. *Compend Continuing Educ Dent* 1994; 15:152-62.
7. Scipioni A, Bruschi GB, Calesini G. The edentulous ridge expansion technique: a five-year study. *Int J Periodont Restorat Dent* 1994;14:451-9.
8. Scipioni A, Bruschi GB, Giargia M, Berglundh T, Lindle J. Healing at implants with and without primary bone contact: an experimental study in dogs. *Clin Oral Implants Res* 1997;8: 39-47.
9. Scipioni A, Bruschi GB, Calesini G, Bruschi E, De Martino C. Bone regeneration in the edentulous ridge expansion technique: histologic and ultra structural study of 20 clinical cases. *Int J Periodont Restorat Dent* 1999;19:269-77.
10. Pelo S, Boniello R, Gasparini G. Horizontal and vertical ridge augmentation for implant placement in the aesthetic zone. *Int J Oral Maxillofac Surg* 2007;36:944-8.