

# Idiopathic Gingival Enlargement and its Management: A Case Report

Mohammad- Taghi Chitsazi<sup>1</sup> • Adileh Shirmohammadi<sup>2\*</sup> • Abouzar Moradi<sup>3</sup> • Zahra goharfar<sup>4</sup>

<sup>1</sup>Associate Professor, Department of Periodontics, Faculty of Dentistry, Tabriz University of Medical Sciences, Tabriz, Iran

<sup>2</sup>Professors, Department of Periodontics, Faculty of Dentistry, Tabriz University of Medical Sciences, Tabriz, Iran

<sup>3</sup>Assistant Professor, Department of Periodontics, Faculty of Dentistry, Alborz University of Medical Sciences, Iran

<sup>4</sup>Assistant Professor, Department of Periodontics, Faculty of Dentistry, Urmia University of Medical Sciences, Iran

\*Corresponding Author; E-mail: shirmohamadia@yahoo.com

Received: 10 September 2014; Accepted: 7 July 2015

J Periodontol Implant Dent 2015;7(2):61–65 doi: 10.15171/jpid.2015.012

This article is available from: <http://dentistry.tbzmed.ac.ir/jpid>

© 2015 The Authors; Tabriz University of Medical Sciences

This is an Open Access article distributed under the terms of the Creative Commons Attribution License

(<http://creativecommons.org/licenses/by/3.0>), which permits unrestricted use, distribution, and reproduction in any medium, provided the original work is properly cited.

---

## Abstract

Idiopathic or hereditary gingival fibromatosis (HGF) is a relatively rare disease characterized by the enlargement of the gingiva, resulting in functional, esthetics and psychological disturbances. The degree of gingival overgrowth can be defined as: grade 0: no sign of gingival enlargement; grade I: enlargement confined to interdental papilla; grade II: enlargement involves papilla and marginal gingiva; and grade III: enlargement covers three quarters or more of the crown. This case report describes the case of a 16-year-old girl suffering from HGF with chief complaint of gingival swelling. Intraoral examination exhibited diffuse and grade III gingival enlargement in both jaws and also in both surfaces of buccal and lingual/palatal. Treatment included surgery (internal and external gingivectomy) in six sessions, and prescription of antibiotics and 0.2% chlorhexidine mouthwash. Moreover, gingivoplasty was performed in the esthetic zone of maxilla after performing all the surgeries in the mouth. The patient was under regular follow-up visits. The treatment outcomes after six months were satisfactory and no symptoms of recurrence were observed.

**Key words:** Gingival fibromatosis, gingival enlargement, gingivectomy.

---

## Introduction

**H**ereditary gingival fibromatosis (HGF) is the most common syndromic gingival enlargement.<sup>2</sup> Its clinical appearance is usually detected by pink, diffuse, firm and leathery, non-hemorrhagic and asymptomatic gingival enlargement.<sup>3,4</sup> Its prevalence is 1/175000, with equal predilection for men and women.<sup>5,6</sup> The disease often starts at the commencement of permanent dentition, although it may

occur during primary dentition period or at birth time.<sup>7,8</sup> From the localization aspect, it is heterogeneous in a way that it could be localized or generalized, and involves buccal or lingual (palatal) surfaces, and the maxilla or mandible.<sup>9,10</sup> Its growth usually happens simultaneously with tooth eruption; increases during teenage period, decreases in adults and it may disappear with tooth extraction.<sup>4,11,12</sup>

The most prevalent effects of this disease on dentition are diastema, prolonged retention of primary

teeth, delayed eruption and malpositioning of permanent teeth, malocclusion and prominent lips.<sup>4,10,13,14</sup> It would also cause bone loss indirectly by accumulation and deficiency in plaque control. HGF etiology is unknown; however, its origin is hereditary (autosomal dominant or autosomal recessive). The probability of its penetration in the people from the same race is varied and could be complete or incomplete.<sup>15-17</sup>

HGF can occur isolated or accompanied by syndromes. In the syndromic one (Table 1),<sup>18</sup> the most popular signs with gingival enlargement is hypertrichosis.<sup>12,19</sup> Several mechanisms can have a part in the pathogenesis of this condition:<sup>2,20-26</sup> 1) increased collagen synthesis due to TGF- $\beta$ 1 and prolyl 4-hydroxylases (P4Hs) expression; 2) reduction in collagen destruction as a result of an increase in the expression of tissue inhibitor matrix metalloproteinases (TIMP), a decrease in matrix metalloproteinases (MMPs) and creation of crossed-linking in collagen fibers; 3) an increase in fibroblast proliferation because of an increase in TGF- $\beta$ 1 expression; 4) boosted keratinocytes and their stimulatory effects on fibroblasts as an effect of interactions between keratinocytes-fibroblasts. Hereditary gingival fibromatosis should be differentiated from a number of diseases (Table 2)<sup>27</sup> by clinical, laboratory and histological examinations.

### Case Report

A sixteen-year-old girl was referred to the Periodontics Department of Dentistry Faculty in Tabriz University of Medical Sciences. The chief complaint was the gingival swelling all over her mouth that caused esthetic problems and deficiency in chewing and speaking. Gingival enlargement had occurred simultaneously with eruption of permanent teeth and gradually affected the whole dentition. In the dental history, the patient mentioned a gingivectomy procedure about 5 years previously that had recurred in the current situation.

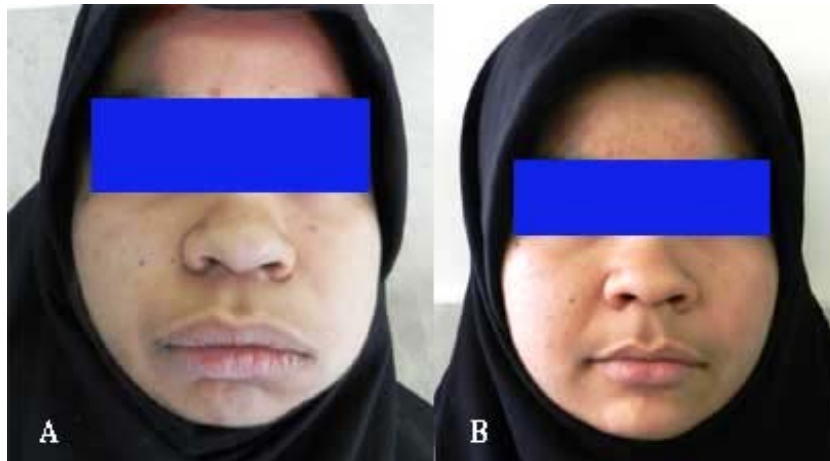
The patient's medical history was unremarkable and did not reveal any drug-induced gingival enlargement. In the familial history, this condition was not seen in parents and other family members but it had been reported in her father's cousin. Facial asymmetry and hypertrichosis was detected in extraoral examination (Figure 1); however, there was no evidence of mental deficiency. Intraoral examination exhibited diffuse and grade III gingival enlargement in both jaws and also in both buccal and lingual/palatal surfaces (Figure 2). The gingival consistency was fibrous and its color was pinkish red that covered all tooth surfaces except the incisal edges and occlusal surfaces of some teeth. Moreover, gingival enlargement on the left side was more se-

**Table 1. Syndromes associated with HGF**

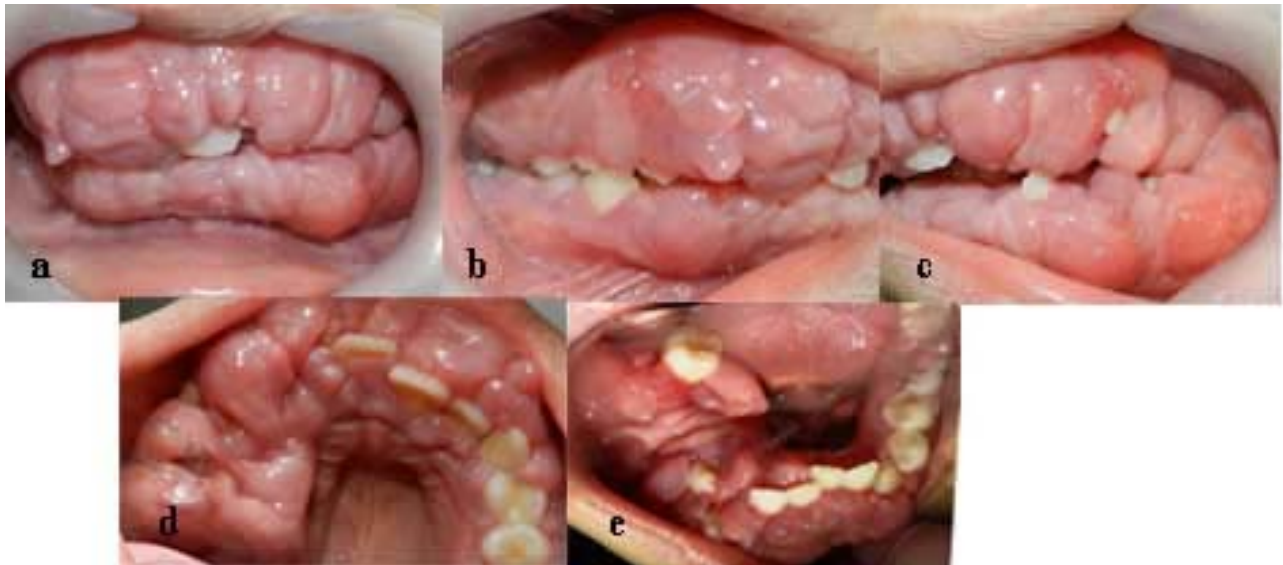Associated Syndromes	Main Features
Gingival fibromatosis with hypertrichosis Zimmer-man Laband	Gingival fibromatosis, hypertrichosis, mental retardation, muscular hypotonia Gingival fibromatosis, abnormal fingers, fingernails, nose, and ears, hepatosplenomegaly, hyperextensible metacarpophalangeal joints
Rutherford (Oculo-dental)	Gingival fibromatosis, corneal dystrophy/opacity, aggressive behavior, mental retardation
Cross	Gingival fibromatosis, microphthalmia, mental retardation, hypopigmentation
Murray-Puretic Drescher's (Juvenile hyaline fibromatosis)	Gingival fibromatosis, involvement of bones, joints, cartilage, skin, Muscles, infection
Ramon	Gingival fibromatosis, seizures, stunted growth, juvenile rheumatoid arthritis, cherubism, hypertrichosis, mental retardation
Prune-belly	Gingival fibromatosis, Absence of abdominal muscles, facial dimorphism, abnormality of urinary tract
Jones	Gingival fibromatosis, progressive deafness, maxillary odontogenic cysts and undescended testis

**Table 2. Generalized gingival enlargements that might mimic HGF**

Generalized symmetric enlargements	Generalized nodular enlargements
Amyloidosis	Neurofibromatosis (type 1 and 2)
Sturge Weber syndrome	Gardner's syndrome
Wegener's granulomatosis	Cowden's syndrome
Sarcoidosis	Tuberous sclerosis
Oro-facial granulomatosis	
Leukemia (Acute myeloid leukemia)	
Drugs induced gingival enlargement (phenytoin, cyclosporine, and calcium channel blockers)	
Plaque induced gingival hyperplasia	
Plasma cell gingivitis	
Crohn's disease	



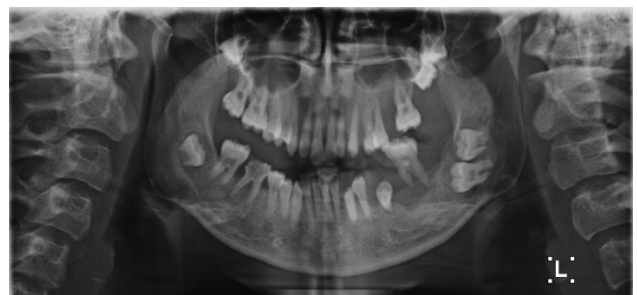**Figure 1.** Frontal view of the patient: a) Preoperative facial asymmetry and hypertrichosis; b) 6 months postoperatively, showing good esthetic results.



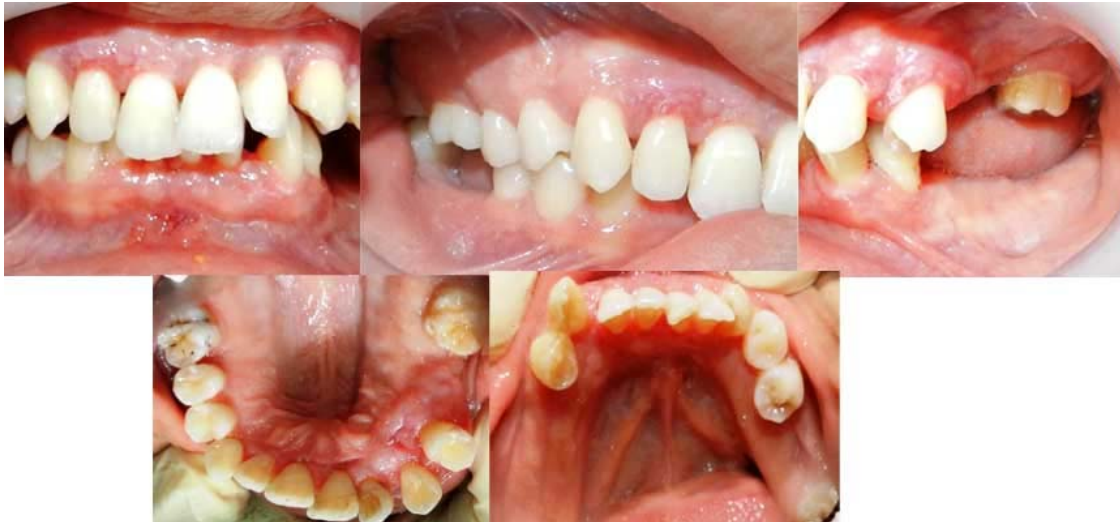**Figure 2.** Intraoral views of the patient: A) frontal views; B) lateral view (right side); C) lateral view (left side); D) upper occlusal view; E) lower occlusal view.

vere than on the right side. In the radiographic view generalized bone loss was observed that was severe in the left first molars that indicated the probability of aggressive periodontitis along with gingival enlargement. In addition, the left second molars were unerupted (Figure 3). Hematologic evaluation of the patient was normal. In histological evaluation of lesions, an increase in connective tissue with condensed collagen fibers along with light infiltration with persistent inflamed cells was seen. Based on clinical and histological findings, and medical and family history of the patient, HGF was diagnosed. Treatment included surgery (internal and external gingivectomy) in six sessions, with prescription of antibiotic and 0.2% chlorhexidine mouthwash. Moreover, gingivoplasty was performed in the esthetic zone of maxilla after performing all the surger-

ies in the mouth. The patient was under regular follow-up visits. The treatment outcomes after six months were satisfactory and no symptoms of recurrence were observed (Figures 1 to 4).



**Figure 3.** Panoramic radiograph of the patient showing generalized bone loss that was severe in the left first molars.



**Figure 4.** The treatment outcomes after six months were satisfactory and no symptoms of recurrence were observed.

### Discussion

HGF is heterogeneous from clinical and genetic aspects as well as pathogenesis. It usually starts simultaneously with tooth eruption and disappears by their extraction. This shows that the tooth or its adjacent plaque can play an important role in the onset of this condition. HGF could be isolated or accompanied by syndromes. The reported case was in the syndromic group (HGF-hypertrichosis syndrome). There is controversy over the HGF treatment initiation in children. Some researchers believe that it is desirable to wait until adolescence; as a matter of fact there is probability of recurrence in this period. Of course the delay in initiating treatment leads to prolonged retention of primary teeth, delayed eruption and malposition in permanent teeth, disturbances in function and esthetic and psychological complications.<sup>4,12,16,28-30</sup> Accordingly, it is preferable to start the treatment at the time of diagnosis with the patient complaint and disturbances in normal function. HGF treatment includes scaling and root planing (SRP), oral hygiene instruction (OHI) or surgery depending on its severity.<sup>3,31,32</sup>

The incidence of disease recurrence could not be anticipated; however, its probability in teenagers is more than adults and is faster in regions with plaque.<sup>4,5,33</sup> In conclusion, proper plaque control along with accurate and short-term follow-up visits could be effective in reducing the recurrence risk of this condition.

### References

1. Bokenkamp A, Bohnhorst B, Beier C, et Al. Nifedipine Aggravates Cyclosporine A-Induced Hyperplasia. *Pediatr Nephrol* 1994;8:181-185. doi: [10.1007/bf00865474](https://doi.org/10.1007/bf00865474)
2. Doufexi A, Mina M, Loannidou E. Gingival Overgrowth In Children: Epidemiology, Pathogenesis And Complication. A Literature Review. *J Periodontol* 2005;76:3-10. doi: [10.1902/jop.2005.76.1.3](https://doi.org/10.1902/jop.2005.76.1.3)
3. Richardo D, Coletta Graner E. Hereditary Gingival Fibromatosis: A Systematic Review. *J Periodontol* 2006;77:753-764. doi: [10.1902/jop.2006.050379](https://doi.org/10.1902/jop.2006.050379)
4. Bozzo L, Machado Ma, De Almedia Op, Coletta Rd, Lopes Ma. Hereditary Gingival Fibromatosis: Report Of Three Cases. *J Clin Pediatr Dent* 2000;25:41-46.
5. Ramer M, Marrone J, Stahl B, Burakoff R. Hereditary Gingival Fibromatosis: Identification, Treatment, Control. *J Am Dent Assoc* 1996;127:493-495. doi: [10.14219/jada.archive.1996.0242](https://doi.org/10.14219/jada.archive.1996.0242)
6. Kather J, Salgado MAC, Salgado UFL, Cortelli JR, Pallos D. Clinical and histomorphometric characteristics of three different families with hereditary gingival fibromatosis. *Oral Surgery, Oral Medicine, Oral Pathology, Oral Radiology and Endodontology* 2008;105:348-52. doi: [10.1016/j.tripleo.2007.06.006](https://doi.org/10.1016/j.tripleo.2007.06.006)
7. Vikender SY, Souvik Ch, Shikha T, Rajinder KSh. An unusual case of idiopathic gingival fibromatosis. *Contemp Clin Dent* 2013;4:102-4. doi: [10.4103/0976-237x.111623](https://doi.org/10.4103/0976-237x.111623)
8. Hanefer E, Kay L. Congenital Idiopathic Gingival Fibromatosis In The Deciduous Dentition. *Oral Surg Oral Med And Oral Path* 1965;24:65-70. doi: [10.1016/0030-4220\(67\)90292-7](https://doi.org/10.1016/0030-4220(67)90292-7)
9. Katz J, Guelmann M, Barak S. Hereditary Gingival Fibromatosis With Distinct Dental, Skeletal, And Developmental Abnormalities. *Pediatr Dent* 2002;24:253-6. doi: [10.1016/0278-2391\(88\)90229-7](https://doi.org/10.1016/0278-2391(88)90229-7)
10. Bozzo L, de Almedia OP, Scully C, Aldred MJ. Hereditary Gingival Fibromatosis: Report of An Extensive Four-Generation Pedigree. *Oral Surg Oral Med Oral Pathol* 1994;78:452-4.
11. Danesh-Meyer MJ, Holborow DW. Familial Gingival Fibromatosis: A Report of Two Patients. *N Z Dent J* 1993;89:119-22.
12. Cuestas-Carnero R, Bornancini CA. Hereditary Gingival Fibromatosis Associated With Hypertrichosis: Report of Five Cases In One Family. *J Oral Maxillofac Surg* 1988;46:415-420.



13. Kelekis-Cholakakis A, Wiltshire Wa, Birek C. Treatment And Long-term Follow Up Of A Patient With Hereditary Gingival Fibromatosis: A Case Report. *J Can Dent Assoc* 2002;68:290-294.
14. Baptista IP. Hereditary Gingival Fibromatosis: A Case Report. *J Clin Periodontol* 2002;29:871-4. doi: [10.1034/j.1600-051x.2002.290913.x](https://doi.org/10.1034/j.1600-051x.2002.290913.x)
15. Raesta Am, Collan Y, Kilpinen E. Hereditary Fibrous Hyperplasia Of The Gingiva With Varying Penetrance And Expressivity. *Scand J Dent Res* 1978;86:357-365. doi: [10.1111/j.1600-0722.1978.tb00638.x](https://doi.org/10.1111/j.1600-0722.1978.tb00638.x)
16. Emerson Tg. Hereditary Gingival Hyperplasia: A Family Pedigree Of Four Generations. *Oral Surg Oral Med Oral Pathol* 1965;19:1-9. doi: [10.1016/0030-4220\(65\)90207-0](https://doi.org/10.1016/0030-4220(65)90207-0)
17. Thomas CH, Debora P, Donald W B, Joey B, Mark JP, Jose R C. Genetic Linkage of Hereditary Gingival Fibromatosis to Chromosome 2p21. *Am J Hum Genet* 1998;62:876-883. doi: [10.1086/301797](https://doi.org/10.1086/301797)
18. Haytac MC, Ozcelik O. The Phenotypic Overlap Of Syndromes Associated With Hereditary Gingival fibromatosis: Follow-Up Of A Family For five Years. *Oral Surg Oral Med Oral Pathol Oral Radiol Endod* 2007;103:521-527. doi: [10.1016/j.tripleo.2006.02.021](https://doi.org/10.1016/j.tripleo.2006.02.021)
19. Mangino M, Pizzuti A, Dallapiccola B, Bonfante A, Saccilotto D, Cucchiara E. Hereditary Gingival Fibromatosis (HGF) With Hypertrichosis Is Unlinked To The HGF1 And HGF2 Loci. *Am J Med Genet A* 2003;116:312-314. doi: [10.1002/ajmg.a.10850](https://doi.org/10.1002/ajmg.a.10850)
20. Coletta RD, de Almedia OP, Graner E. Differential Proliferation of Fibroblasts Cultured From Hereditary Gingival Fibromatosis And Normal Gingiva. *J Periodontol Res* 1998;33:469-475. doi: [10.1111/j.1600-0765.1998.tb02346.x](https://doi.org/10.1111/j.1600-0765.1998.tb02346.x)
21. Barros SP, Merzel J, de Arajo VC, de Almeida OP, Bozzo L. Ultrastructural aspects of connective tissue in hereditary gingival fibromatosis. *Oral Surg Oral Med Oral Pathol Oral Radiol Endod* 2001;92:78-82. doi: [10.1067/moe.2001.115026](https://doi.org/10.1067/moe.2001.115026)
22. Kather J, Castillo-Salgado MA, Lodi-Salgado UF, Pallos D, Cortelli JR. Clinical And Histomorphometric Characteristics Of Three Different Families With Hereditary Gingival fibromatosis. *Oral Surg Oral Med Oral Pathol Oral Radiol Endod* 2008;105:348-52. doi: [10.1016/j.tripleo.2007.06.006](https://doi.org/10.1016/j.tripleo.2007.06.006)
23. Almeida JP, Coletta RD, Silva SD, Agostini M, Vargas PA, Bozzo L, Graner E. Proliferation of Fibroblasts Cultured From Normal Gingiva and Hereditary Gingival Fibromatosis Is Dependent on Fatty Acid Synthase Activity. *J Periodontol* 2005;76:272-8. doi: [10.1902/jop.2005.76.2.272](https://doi.org/10.1902/jop.2005.76.2.272)
24. Meng L, Ye X, Fan M, Xiong X, Von den Hoff WJ, Bian Zh. Keratinocytes Modify fibroblast Metabolism In Hereditary Gingival Fibromatosis. *Oral Biology* 2008;53:1050-7. doi: [10.1016/j.archoralbio.2008.05.011](https://doi.org/10.1016/j.archoralbio.2008.05.011)
25. Meng L, Huang M, Ye X, Fan M, BianZh. Increased Expression Of Collagen Prolyl 4-Hydroxylases In Chinese Patients With Hereditary Gingival fibromatosis. *Oral Biology* 2007;52 :1209-14. doi: [10.1016/j.archoralbio.2007.07.006](https://doi.org/10.1016/j.archoralbio.2007.07.006)
26. Cotrin P, de Andrade CR, Graner E, Almeida OP, Sauk JJ, Coletta RD. TGF-B1 Autocrine Stimulation Regulates Fibroblast Proliferation In Hereditary Gingival Fibromatosis. *J Periodontol* 2001;72:1726-33. doi: [10.1902/jop.2001.72.12.1726](https://doi.org/10.1902/jop.2001.72.12.1726)
27. Khan U, Mustafa S, Saleem Z, Azam A , Ahmed Khan Z. Hereditary Gingival Fibromatosis Diagnosis And Treatment. *Pakistan Oral & Dental Journal* 2012;32:226-231.
28. Kavvadia K, Pepelassi E, Alexandridis C, Arkadopoulou A, Polyzois G, Tossios K. Gingival Fibromatosis and Significant Tooth Eruption Delay In An 11-Year-Old Male: A 30-Month Follow Up. *Int J Pediatr Dent* 2005;15:294-302. doi: [10.1111/j.1365-263x.2005.00646.x](https://doi.org/10.1111/j.1365-263x.2005.00646.x)
29. Bittencourt LP, Campos V, Moliterno LF, Ribeiro DP, Sampaio RK. Hereditary Gingival Fibromatosis: Review Of Literature And A Case Report. *Quintessence Int* 2000;31:415-8.
30. Baptista Ip. Hereditary Gingival Fibromatosis: A Case Report. *J Clin Periodontol* 2002;29:871-4. doi: [10.1034/j.1600-051x.2002.290913.x](https://doi.org/10.1034/j.1600-051x.2002.290913.x)
31. Seki K, Sato S, Asano Y, Akutagawa H, Ito K. Improved pathologic teeth migration following gingivectomy in a case of idiopathic gingival fibromatosis. *Quintessence Int* 2010;41:543-5.
32. Ramnarayan BK, Sowmya K, Rema J. Management of idiopathic gingival fibromatosis: Report of a case and literature review. *Pediatr Dent* 2011;33:431-6.
33. Martelli-Junior H, Lemos DP, Silva CO, Graner E, Coletta RD. Hereditary Gingival Fibromatosis: Report Of A Five-Generation Family With Cellular Proliferation Analysis. *J Periodontol* 2005;76:2299-305. doi: [10.1902/jop.2005.76.12.2299](https://doi.org/10.1902/jop.2005.76.12.2299)